Linksventrikuläre non-compaction Kardiomyopathie (LVNC)

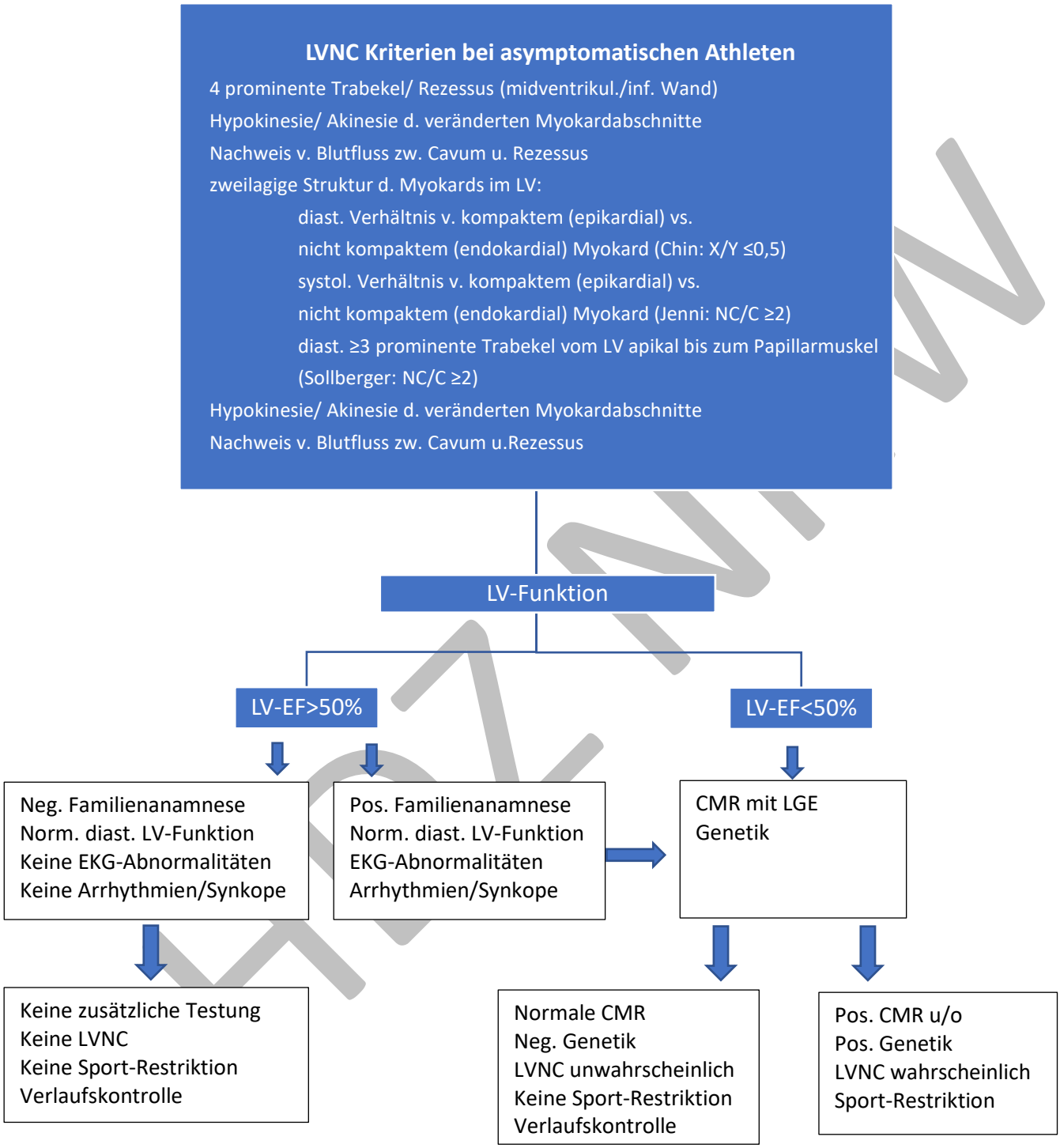

Literatur:

- Dhutia H, Malhotra A, Yeo TJ, et al. Inter-rater reliability and downstream financial implications of electrocardiography screening in young athletes. Circ Cardiovasc Qual Outcomes 2017;10:e003881.
- Gati S, Papadakis M, Papamichael ND, et al. Reversible de novo left ventricular trabeculations in pregnant women: implications for the diagnosis of left ventricular noncompac- tion in low-risk populations. Circulation 2014;130:475–483.
- Zemrak F, Ahlman MA, Captur G, Mohiddin SA, Kawel-Boehm N, Prince MR, Moon JC, Hundley WG, Lima JAC, Bluemke DA, Petersen SE. The relationship of left ventricular trabeculation to ventricular function and structure over a 9.5- year follow-up: the MESA study. J Am Coll Cardiol 2014;64:1971–1980.
- Caselli S, Ferreira D, Kanawati E, Di Paolo F, Pisicchio C, Attenhofer Jost C, Spataro A, Jenni R, Pelliccia A. Prominent left ventricular trabeculations in competitive athletes: a proposal for risk stratification and management. Int J Cardiol 2016;223:590–595..

Linksventrikuläre non-compaction Kardiomyopathie (LVNC) vs Sportherz

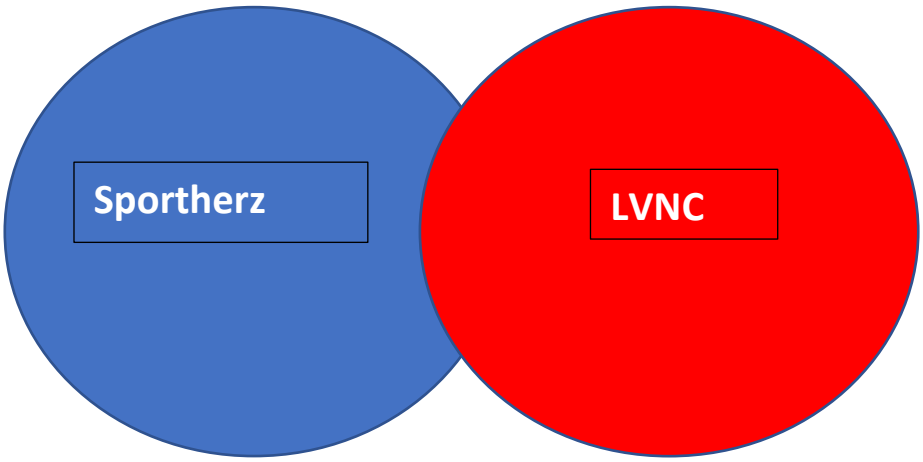

-	Symptome	+
-	Familienanamnese	+
-	Syst. oder diast. Dysfunktion	+
-	WBS im Stress-Echo	+
-	Belastungsinduzierte Arrhythmien	+
-	Peak VO2 < 100% pred.	+
-	Myokardfibrose	+
-	Familienscreening	+
-	Keine Regression nach Sportpause	+

HDZ NRW